

BREAST CANCER IRRADIATION USING PROTON PENCIL BEAM SCANNING

A. Pasztorova
J. Kubes
M. Andrlik
B. Ondrova
G. Kasacova
K. Dedekova

P. Vitek
S. Slavikova
S. Vinakurau
J. Kvech
V. Vondracek
M. Navratil

/ Proton Therapy Center Czech

PURPOSE:

Proton therapy using pencil beam scanning (PBS) in the breast cancer irradiation allows achieving a perfect coverage of the target volumes while maximizing the sparing of heart, coronal arteries, contralateral breast and lungs. This was demonstrated by several dosimetric and clinical studies. It is necessary as for the other dynamic irradiation techniques to suppress influence of breathing interplay effect to the final dose distribution. Moreover proton therapy using PBS brings other requirements for patient setup precision. Just

filling of all these requirements allows to change perfect looking treatment plans into the clinical usage.

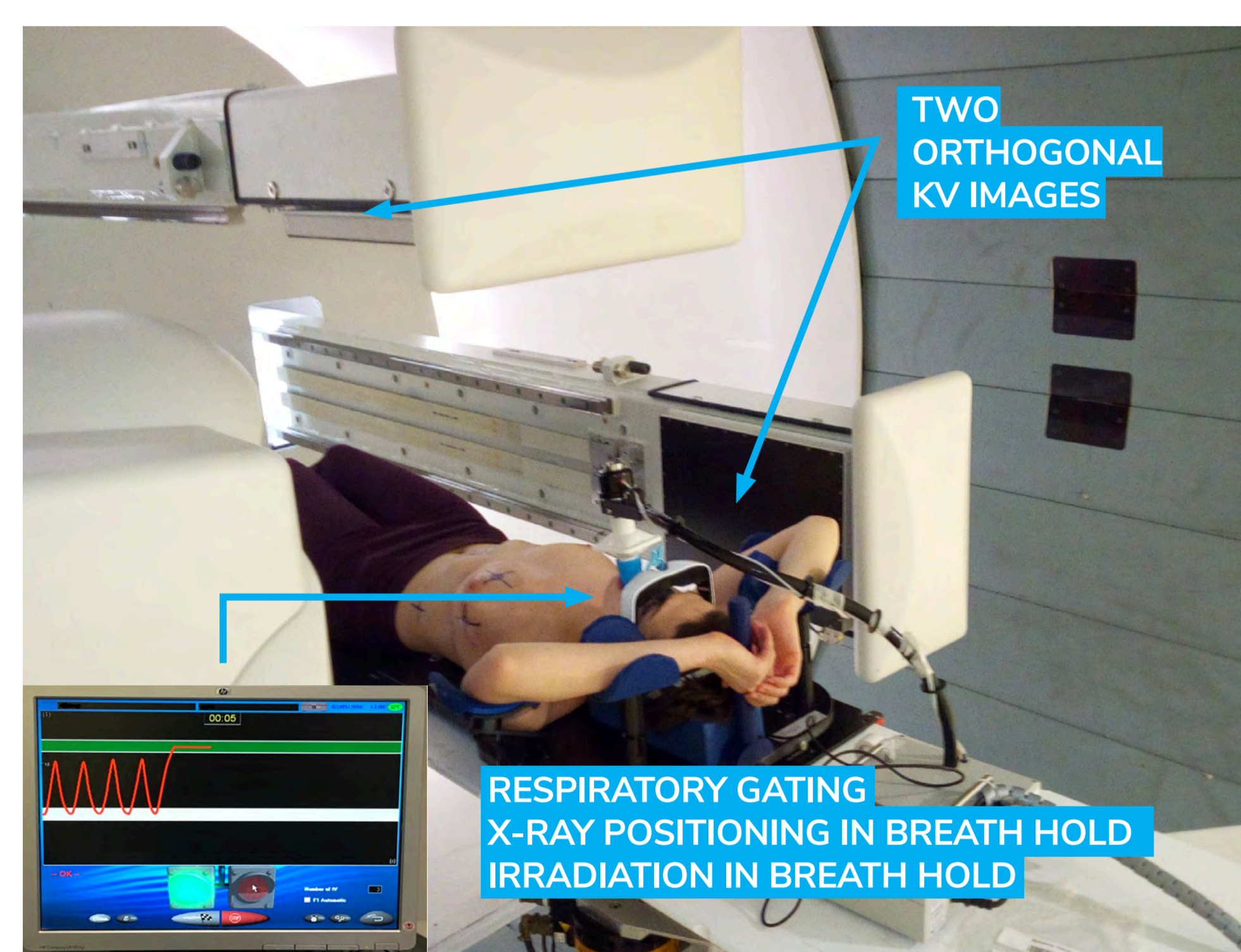
MATERIALS AND METHODS:

From April 2015 to September 2017 forty-two patients with breast cancer were treated by the PBS. The average age was 55 (min. 25 years, max 75 years). The staging was from pTis to pT3 (2x pTis, 5x pT1b, 21xpT1c, 12x pT2 and 2x pT3). There were 39 patients with left-side tumor and 3 patients with right-side tumor. 11 patients were

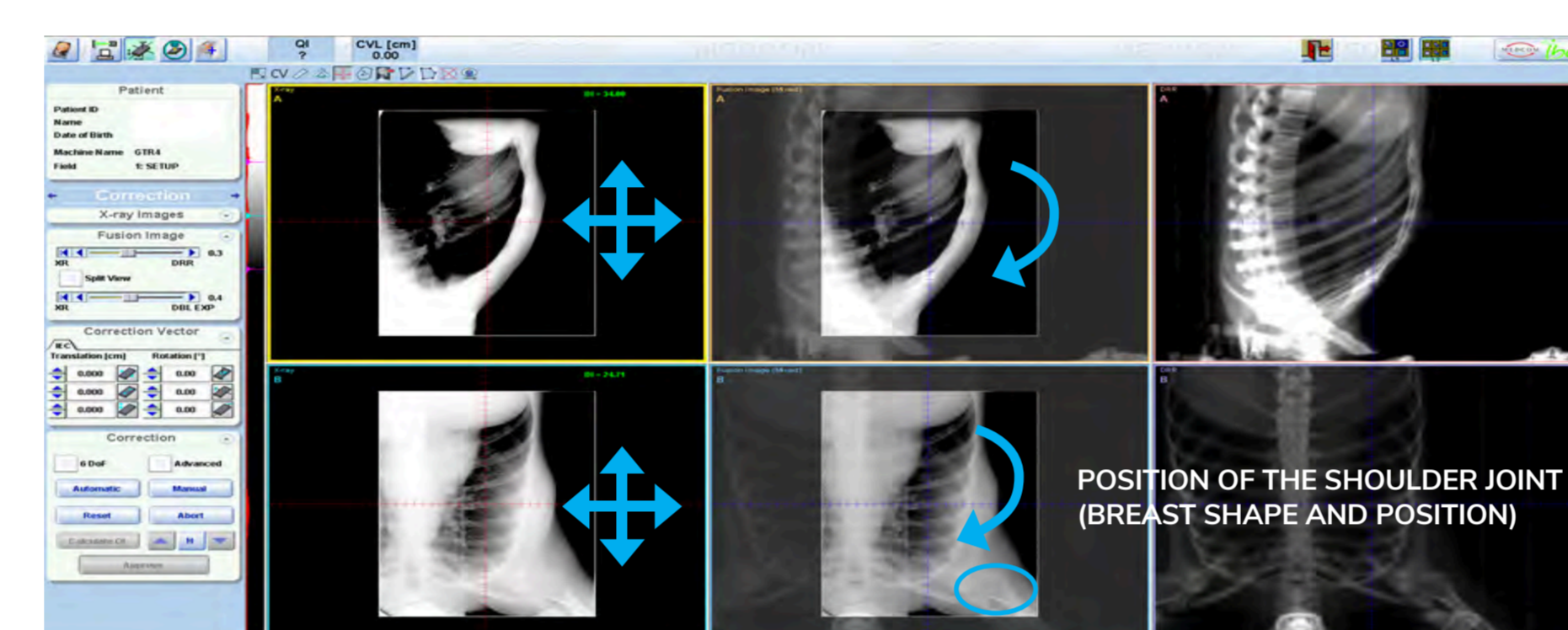
treated with locoregional irradiation (nodes included) and 31 patients were treated for breast only. The selected fractionation was standard (25x2) + boost (8x2) for 29 patients, accelerated (16x2,67) + boost (4x2,5) for 11 patients, (16x2,67) with no boost for 1 patient, and one patient had Simultaneously Integrated Boost (28x1,85+ 28x2,25). There were evaluated: acute and late toxicity, dosimetric parameters of ipsilateral lung, contralateral lung, heart (right and left atrium and ventricle), right and left coronal arteria (incl. LAD, r. circumflexus) and contralateral breast.

SETUP PROTOCOL: The two-step patient setup protocol was used. Both steps are performed during deep inspiration breath hold using a Dyn'R spirometer.

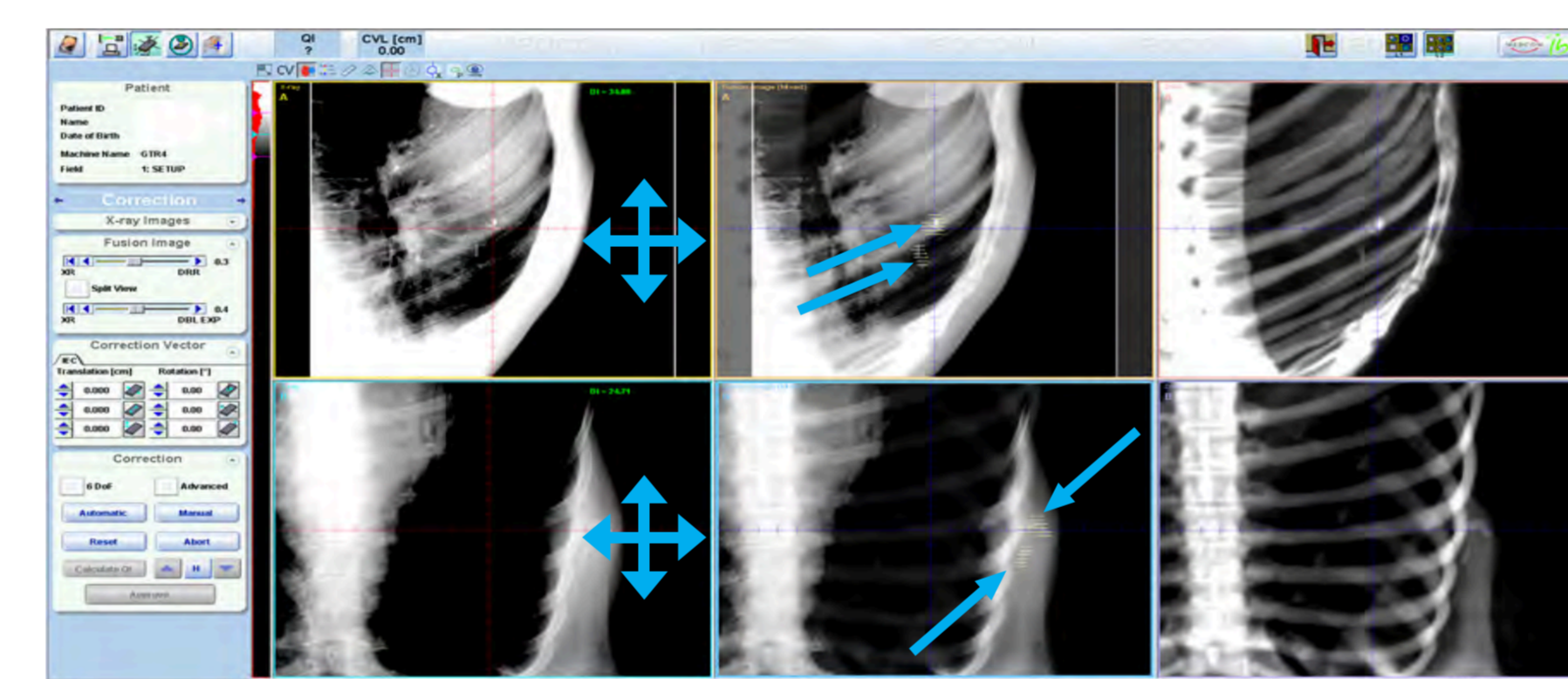
DEEP INSPIRATION BREATH HOLD IMAGE ACQUISITION USING DYN'R



TWO STEP KV IMAGE MATCHING



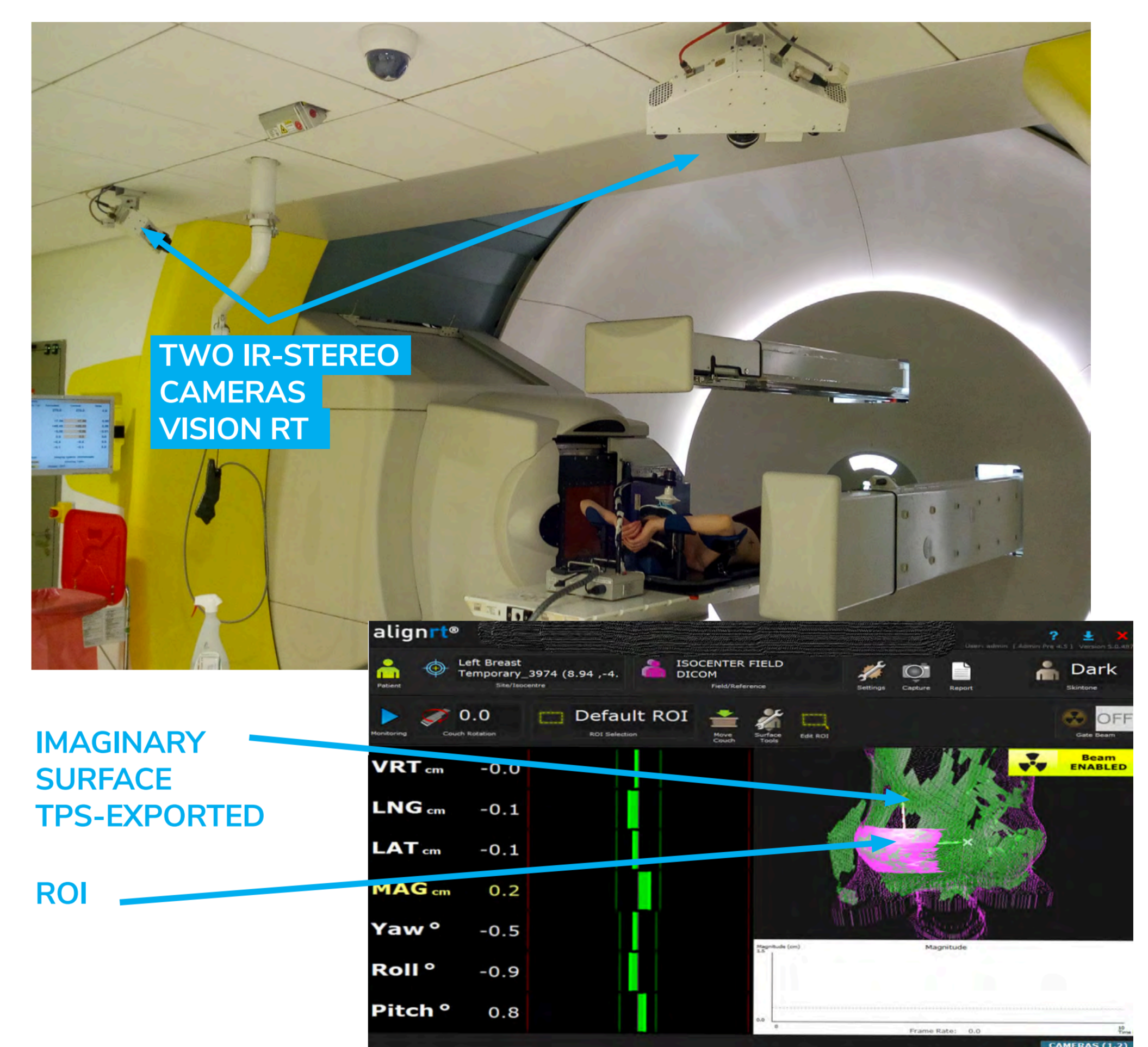
The digitally reconstructed radiograms (DRRs) for all directions of rotation and translation assessment are matched. It is necessary to observe the position of the shoulder-joint as this has proven important to manage breast shape and position.



In the second step, X-ray contrast post-surgery markers in combination with breast surface position is used.

FINAL VERIFICATION OF BODY SURFACE AND SHAPE BY IR STEREO-CAMERAS

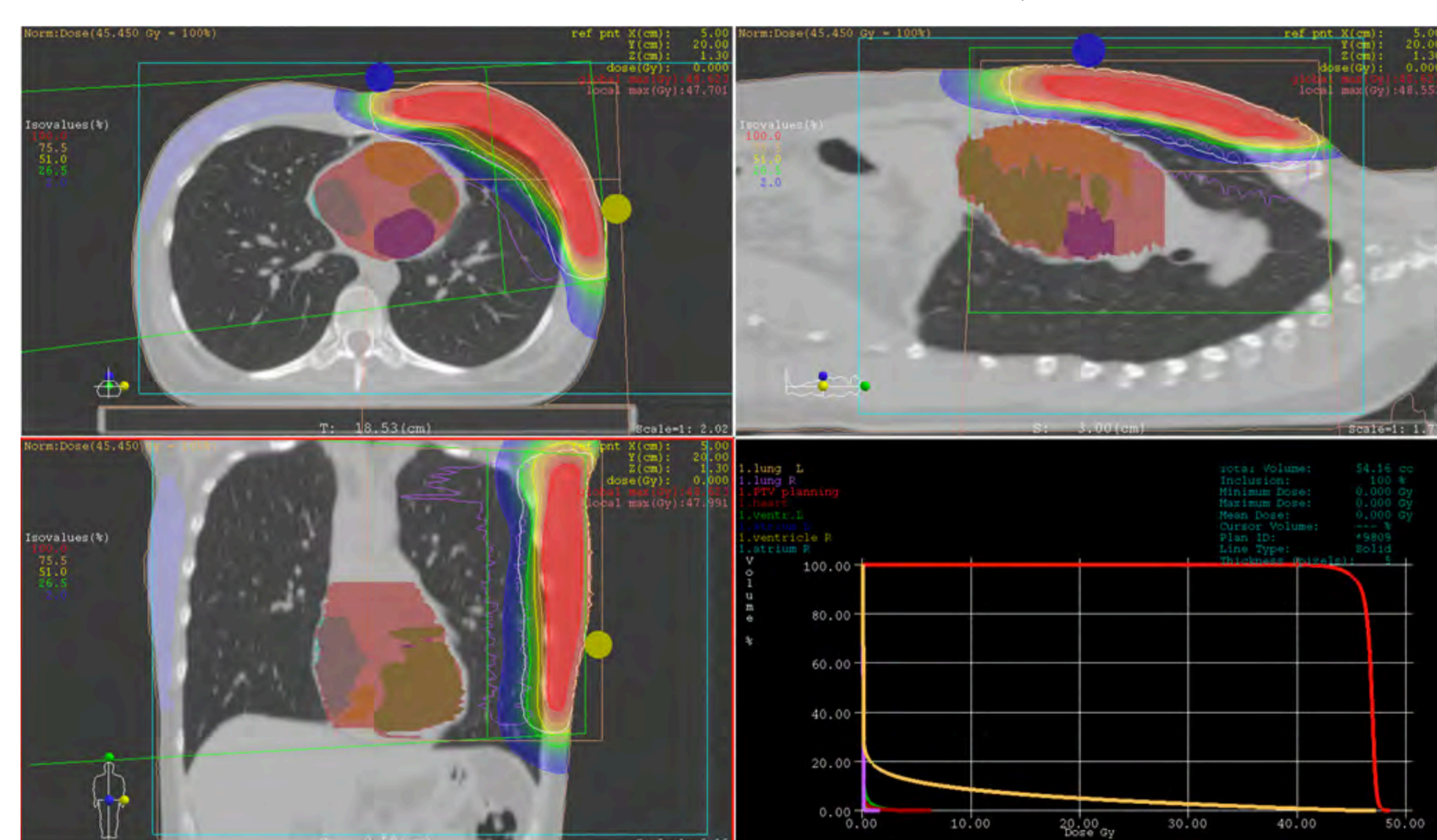
The surface position is matched with the patient reference surface using two infrared stereoscopic cameras (Vision RT system). The image acquisition proceed simultaneously with kV imaging. The reference surface is exported directly from the treatment planning system.



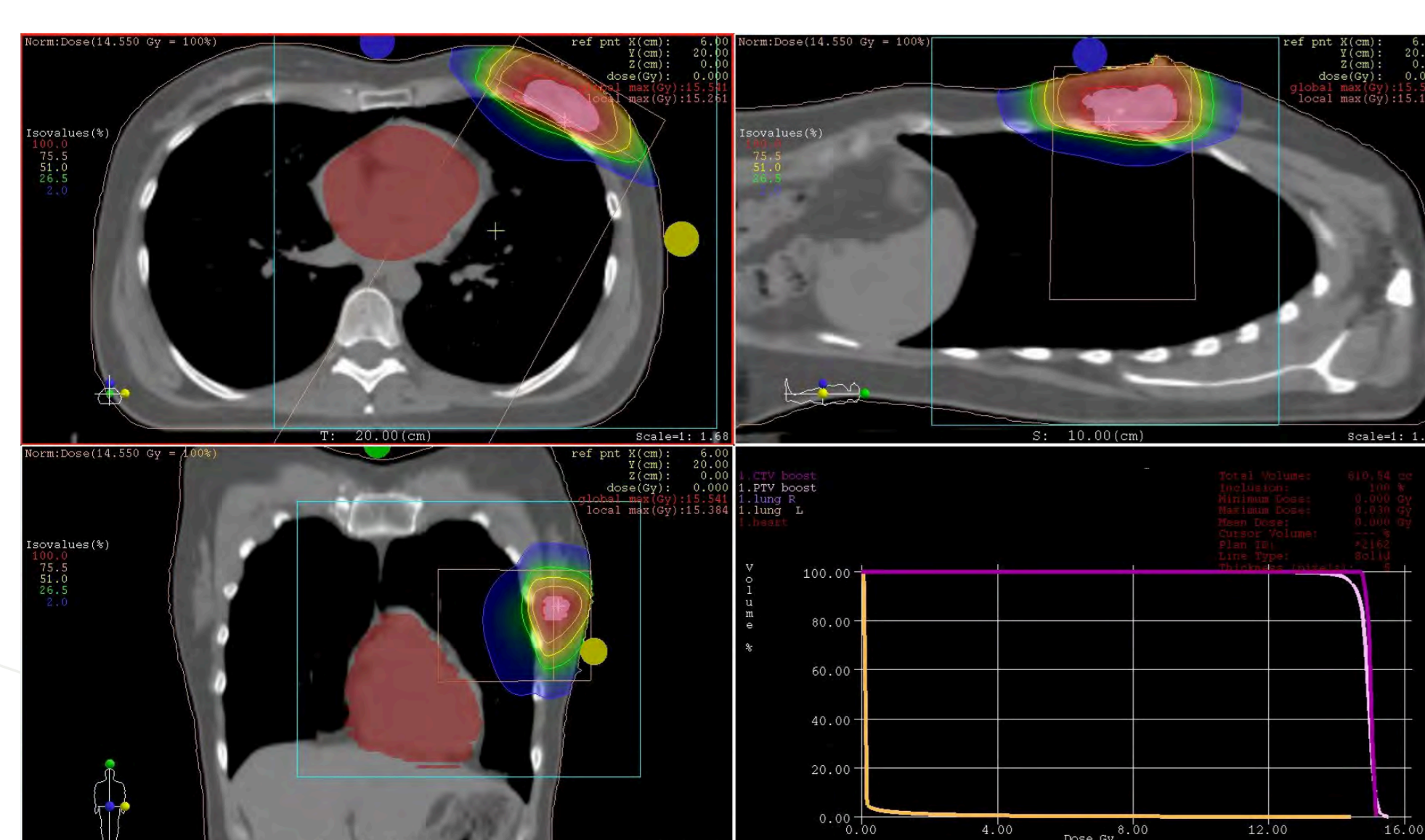
PLANNING:

A treatment plan consists of one direct field in the case of small non-arched breasts. A two-field irradiation technique was used for bigger more arched breasts. These two fields should avoid the tangential impact of the proton beam. The first beam has a gantry angle of 0° or very close to this angle. The second field is orthogonal to the first field or slightly inclined to the first field. The dose has been reduced to approximately 90% of the prescribed dose in the subcutaneous tissue. The QA plans were calculated for these treatments and the robustness was evaluated with a 5 mm field shift in every direction.

TWO-FIELD PLANNING TECHNIQUE



BOOST IRRADIATION



RESULTS:

All patients have finished radiotherapy without interruption. Observation median was 7 months. The dosimetry parameters are published in following table.

Acute toxicity was evaluated by RTOG criteria. The acute toxicity G1 was reported in 23 patients (55%), G2 in 18 patients (43%), G3 in 1 patient (2%). The late toxicity was reported in 12 patients (54%), G1 in 7 patients (32%), G2 in 3 patients (14%). No relapse was observed.

CONCLUSIONS:

Pencil beam scanning proton therapy (for left-side breast cancer) while using DIBH and body surface detection is feasible, with good reproducibility and minimal acute toxicity. We consider it especially suitable for patients with left-side breast cancer:

- when dose-heart for photon therapy is clinically unacceptable (D_{mean} whole heart, LAD, eventually contralateral breast)
- with cardiac diseases, where dose limits used to be significantly lower
- with genetic syndromes predisposing increased toxicity

PBS proton therapy for breast cancer treatment has acceptable acute and late skin toxicity. It allows to reach minimal doses to the heart, coronal arteries, lungs, contralateral breast and integral dose at all. This reduces the risk of cordial toxicity, pulmonary toxicity and secondary malignancies.

This should be beneficial to patients with long life expectancy and also to patients with associated heart diseases.

www.ptc.cz

PROTON THERAPY CENTER

targeting cancer